

Evaluation of different transvaginal sonographic diagnostic parameters in women with postmenopausal bleeding

G. Weber, E. Merz, F. Bahlmann and B. Rösch

Clinic of Obstetrics and Gynecology, University of Mainz, Germany

Key words: POSTMENOPAUSAL BLEEDING, TRANSVAGINAL SONOGRAPHY, ENDOMETRIAL ASSESSMENT, ENDOMETRIAL THICKNESS, ENDOMETRIAL BORDER, ENDOMETRIAL MORPHOLOGY

ABSTRACT

Objective To determine whether the accuracy of transvaginal sonography to detect endometrial pathology is enhanced by assessing endometrial morphology and the regularity of the endometrial border in addition to measurement of endometrial thickness in women with postmenopausal bleeding.

Design and methods A total of 159 women with postmenopausal bleeding were included in a prospective study performed at the Clinic of Obstetrics and Gynecology, University of Mainz. The results obtained on transvaginal sonographic assessment of the endometrium were compared with the histological evaluation of the operative endometrial specimen.

Results A cut-off level for endometrial thickness of 5 mm had a sensitivity of 94%, specificity of 48% and positive and negative predictive values of 69% and 87%, respectively for the presence of endometrial pathology. Assessment of the regularity of the endometrial border showed a sensitivity of 75%, specificity of 66% and positive and negative predictive values of 73% and 69%, respectively. For the third sonographic parameter, endometrial morphology, the sensitivity was 82%, specificity 64%, the positive predictive value 73% and the negative predictive value 74%. The combined consideration of the three sonographic parameters showed a sensitivity of 97%, specificity of 65%, and positive and negative predictive values of 80% and 94%, respectively.

Conclusion The combined evaluation of endometrial thickness, endometrial morphology and the endometrial border enhances the accuracy of transvaginal sonography to detect endometrial pathology in women with postmenopausal bleeding, thus facilitating the decision regarding further diagnostic and therapeutic measures.

INTRODUCTION

In the majority of patients, postmenopausal bleeding is the sole symptom of the presence of endometrial carcinoma¹. However, endometrial carcinoma is diagnosed in only approximately 10–15% of women with postmenopausal bleeding². Dilatation and curettage (D&C) is the most widely used method in patients with postmenopausal bleeding to obtain an endometrial specimen for histological evaluation. Nevertheless, curettage is an expensive, invasive operative procedure associated with some morbidity and even mortality and false-negative findings. Furthermore, no malignancy is detected in 85–90% of women undergoing curettage².

The high-resolution probes used for transvaginal sonography allow the detailed assessment of the organs of the lower pelvis, thus making it a suitable diagnostic technique for use in hospitals and outpatient centers. As early as 1986, Fleischer and co-workers³ demonstrated that endometrial thickness could be assessed with a high degree of accuracy using transvaginal sonography. A number of researchers compared endometrial thickness measured on transvaginal sonography in women with postmenopausal bleeding with the respective histological measurements. However, these workers used different cut-off levels for endometrial thickness, and varying sensitivities and specificities have therefore been reported^{4–11}. The use of a specific cut-off level always involves the risk of false-positive and false-negative findings, which may influence future diagnostic and therapeutic procedures unfavorably.

It was therefore the aim of the present study to investigate whether, in addition to an evaluation of endometrial thickness, the assessment of endometrial morphology and the regularity of endometrial border may improve the accuracy of transvaginal sonography to detect endometrial pathology in women with postmenopausal bleeding.

METHODS

A prospective study of 159 women with postmenopausal bleeding was undertaken at the Clinic of Obstetrics and Gynecology, University of Mainz. Transvaginal sonographic endometrial findings were compared with the histological evaluation of curettage or hysterectomy specimens. All patients had had amenorrhea for at least 12 months; patients on hormone replacement therapy were excluded from the study, to allow the investigation of a large homogeneous patient population without division into various subgroups. Transvaginal sonography was carried out with the patient on an examination couch when she had an empty bladder. The ultrasound equipment used included the Combison 320, 330 and 530 machines (Kretztechnik, Austria) with 5- or 7.5-MHz vaginal probes (240°/210° angle).

The following sonomorphological parameters were assessed: size of the uterus (length, width, height), endometrial thickness, endometrial morphology (homogeneous, heterogeneous), endometrial border (regular, irregular) (Figures 1 and 2) and the presence of accumulated intrauterine fluid. Sonographic assessment of the endometrium was carried out both in longitudinal section and in cross-section. Endometrial thickness was determined in the longitudinal section at the level of maximum endometrial thickness as an outer-to-outer measurement, i.e. from the myometrium/endometrium border to the endometrium/myometrium border (double layer of the endometrium). In the presence of accumulated intrauterine fluid, the measured fluid level was subtracted from the total thickness of the endometrium. A homogeneous endometrium was defined when the entire endometrial structure was characterized by uniform echogenicity. A heterogeneous endometrium was associated with varying echogenicity. An irregular endometrial border between the endometrium and the myometrium was characterized by an irregular course, while the course of a regular endometrial border was completely smooth. The endometrial parameters were correlated in all cases with the pathological classification of tissue samples as benign, suspicious or malignant.

Histological evaluation of the curettage and hysterectomy specimens was performed in the histology laboratory of the Clinic of Obstetrics and Gynecology, University of Mainz. Grading of the histological findings was carried out in accordance with the definitions of the International Society of Gynecological Pathology. The following histological findings were classified as normal: resting endometrium, atrophic endometrium, postmenopausal endometrium. In the suspicious group, abnormal histological findings included: glandular-cystic hyperplasia, adenomatous hyperplasia (grades I–III) and polyps. In the carcinoma group were carcinomas with endometrial differentiation (adenocarcinoma, adenocarcinoid, adenosquamous carcinoma) as well as carcinomas derived from pluripotent Müller's epithelium (mucinous adenocarcinoma, mucoepidermoid adenocarcinoma, clear cell carcinoma). The pathological histology group consisted of

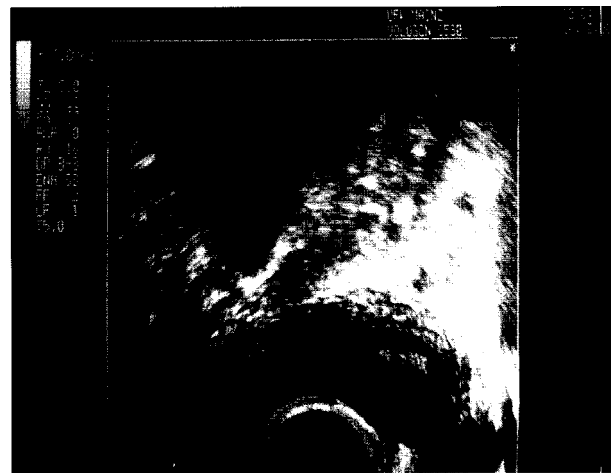


Figure 1 Sonographic view of an endometrium with homogeneous morphology and regular border. Histology: postmenopausal endometrium with irregular proliferation

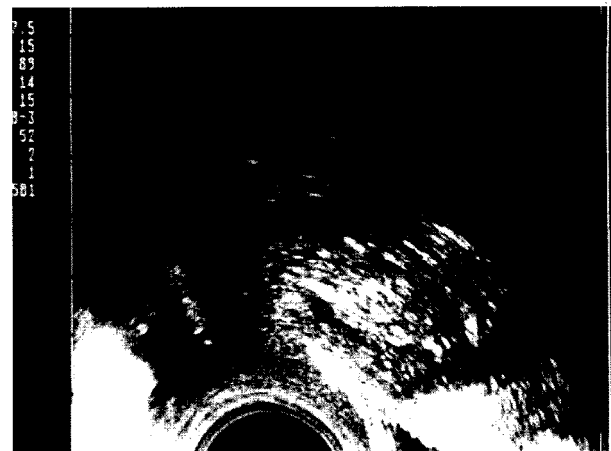

Figure 2 Sonographic view of an endometrium with heterogeneous morphology and irregular border. Histology: endometrium with adenomatous hyperplasia, grade III, and a well-differentiated adenocarcinoma with infiltration into the inner half of the myometrium

patients with abnormal histological findings and cases with identified carcinoma.

Statistical analysis was performed using contingency table analysis. Sensitivity and specificity served as parameters for the validity of the diagnostic procedure. Parameters for the validity of the diagnostic tests were the positive and negative predictive values.

RESULTS

The age of the women participating in the study ranged between 44 and 88 years, the mean (SD) age was 62.4 (10.4) years. The mean (SD) endometrial thickness was 14.8 (11.3) mm. Mean uterine length was 79.7 (18.3) mm, uterine height was 30.8 (11.9) mm and uterine width was 47.4 (12.1) mm.

Out of 159 women, 71 (45%) had benign histology, in 26 (16%) cases the histological finding was suspicious, i.e. glandular-cystic or adenomatous hyperplasia or an endometrial polyp was detected, and in 62 (39%) women histological findings revealed endometrial cancer.

A sonographic endometrial thickness of ≤ 5 mm was measured in 39 (25%) patients. The histological evaluation performed in this group showed benign histology in 87% of patients, a suspicious histology in 10%, i.e. glandular-cystic or adenomatous hyperplasia or an endometrial polyp, and endometrial cancer in one case (3%). In the patient with endometrial cancer and an endometrial thickness of ≤ 5 mm, the histological evaluation showed a flat, dysfunctional endometrium with poorly defined glands. However, on the posterior wall of the uterus a polypous formation was detected, covering a 9×3 -mm area of exophytic growth, consisting of atypical glandular epithelium. The tubular glands were beginning to infiltrate into the wall of the uterus. On sonography, a flat endometrium (≤ 5 mm) with a regular border and a slightly heterogeneous structure was identified, although the partially carcinomatous polyp was missed.

The distribution of normal and pathological histological findings or carcinomas at an endometrial thickness of ≤ 5 mm, 6–10 mm, 11–15 mm and > 15 mm is shown in Table 1.

Table 2 depicts the distribution of normal and pathological histology for a cut-off level of 5 mm in endometrial thickness. A cut-off level of 5 mm, used for the diagnosis of endometrial pathology, was associated with a sensitivity of 94%, a specificity of 48% and positive and negative predictive values of 69% and 87%, respectively.

Of patients with a regular endometrial border, 70% had benign histology and 30% had suspicious histology or carcinoma. In 27% an irregular endometrial border was associated with a normal histological finding and in 73% with a suspicious histology or carcinoma (Table 2). The finding of a sonographic irregular endometrial border had a sensitivity of 75%, a specificity of 66% and positive and negative predictive values of 73% and 69%, respectively at indicating the presence of endometrial disease.

In 75% of cases, there was agreement between sonographic homogeneous endometrial morphology and normal histology; in 25%, agreement between homogeneous endometrial morphology and the histological assessment of endometrial pathology was noted. In the presence of heterogeneous endometrial morphology, the histological finding demonstrated normal histology in 26%, and suspicious histology or carcinoma in 74% (Table 2). A sonographic finding of heterogeneous endometrial morphology was associated with endometrial pathology with a sensitivity of 82%, a specificity of 64% and positive and negative predictive values of 73% and 74%, respectively.

A combined evaluation of the three parameters, i.e. endometrial thickness of up to 5 mm, a regular endometrial border and homogeneous endometrial morphology, resulted in benign histology in 94% of patients and in a suspicious histological finding in 6%. However, no carcinomas were detected. An endometrial thickness of ≥ 5 mm,

Table 1 Incidence of normal and pathological endometrial histology in relation to endometrial thickness (double layer) measured by sonography in 159 patients with postmenopausal bleeding

Endometrial thickness (mm)	Normal histology		Suspicious histology		Endometrial carcinoma	
	n	%	n	%	n	%
0–5 (n = 39)	34	87	4	10	1	3
6–10 (n = 32)	14	44	8	25	10	31
11–15 (n = 33)	9	27	10	30	14	43
> 15 (n = 55)	14	25	4	8	37	67

Table 2 Distribution of normal and pathological histology at a cut-off level of 5 mm in endometrial thickness, in the presence of regular or irregular endometrial border or in the presence of homogeneous or heterogeneous endometrial morphology

Thickness (mm)	Histology	
	Normal (n)	Pathological (n)
≤ 5	34	5
> 5	37	83
<i>Border</i>		
Regular	48	21
Irregular	24	66
<i>Morphology</i>		
Homogeneous	46	15
Heterogeneous	26	72

an irregular endometrial border and heterogeneous endometrial morphology correlated in 20% of cases with normal and in 80% with suspicious histology or carcinoma (Table 3). Endometrial thickness of up to 5 mm combined with the assessment of endometrial morphology and endometrial border was associated with a sensitivity of 97%, a specificity of 65% and positive and negative predictive values of 80% and 94%, respectively, and served as an indicator of the absence or presence of endometrial pathology (Table 4).

DISCUSSION

Fractionated curettage is a routinely performed diagnostic procedure in women with postmenopausal bleeding. However, the sensitivity and specificity of fractionated curettage for the detection of endometrial pathology have diagnostic limitations. False-negative rates of between 2 and 6% for the diagnosis of endometrial hyperplasia or carcinoma have been reported^{12,13}. In one study, fractionated curettage was performed immediately prior to hysterectomy and in 30 out of 50 (60%) cases less than half of the uterine cavity was curetted¹⁴. Furthermore, in elderly patients who frequently exhibit multiple disorders, fractionated curettage is associated with a slight increase in the morbidity and mortality rates¹³. With a view to these problems and to the fact that in only approximately 15% of women with postmenopausal bleeding is endometrial carcinoma

detected, the need for a non-invasive, cost-effective method for routine use in the assessment of the endometrium becomes apparent.

In the past few years, a number of studies demonstrating the reliability of transvaginal sonography for the assessment of the endometrium and the uterus have been published^{4,5,15-19}. Different cut-off levels for endometrial thickness have been used by the various groups for defining endometrial pathology, resulting in varying degrees of reliability for detecting endometrial disease (Table 5). In 1990 Merz and co-workers¹⁷ performed a study using a cut-off level of 5 mm and found an absence of malignancy at a maximum endometrial thickness of ≤ 5 mm. In a study carried out by the same group in 1996²⁰, an endometrial thickness of 5 mm was established as the standard value in postmenopausal women. In the present study, however, an endometrial carcinoma was found in one patient of the

group with endometrial thickness of ≤ 5 mm. In this case the histological examination confirmed a flat and dysfunctional endometrium and detected a carcinomatous polyp of 9×3 mm in size which was beginning to infiltrate into the posterior uterine wall. The carcinomatous cells were characterized by endometrial differentiation and represented a less aggressive type. Sonography showed slightly heterogeneous endometrial morphology and a regular endometrial border, but missed the polyp. The additional use of hydrososonography may enhance diagnostic reliability in this patient group. At a cut-off level of 5 mm, the sensitivity, specificity, positive predictive value and negative predictive value were 94%, 48%, 69% and 87%, respectively and endometrial pathology was excluded. The results obtained by the present study further demonstrate that an increase in endometrial thickness is associated with a rise in the number of detected endometrial carcinomas (Table 1, Figure 3)

In addition to measuring endometrial thickness, we also investigated the accuracy of the sonomorphological parameters, endometrial morphology (homogeneous/heterogeneous) and endometrial border (regular/irregular) for the assessment of endometrial disease. In our patient population, a number of cases with an irregular endometrial border had a normal histology. An irregular endometrial border is therefore not an irrefutable indicator of malignancy. Both glandular-cystic and adenomatous hyperplasias may, in the absence of carcinoma, be associated

Table 3 Distribution of normal and pathological histology in relation to endometrial thickness, endometrial border and endometrial morphology

	Histology	
	Normal (n)	Pathological (n)
Thickness ≤ 5 mm	30	2
Regular border		
Homogeneous morphology		
Thickness > 5 mm	16	63
Irregular border		
Heterogeneous morphology		

Table 4 Diagnostic accuracy in detecting endometrial pathology of endometrial thickness (double layer), endometrial border and endometrial morphology in 159 patients with postmenopausal bleeding

	Sensitivity (%)	Specificity (%)	Positive predictive value (%)	Negative predictive value (%)
Thickness (≤ 5 mm or > 5 mm)	94 (n = 88)	48 (n = 71)	69 (n = 120)	87 (n = 39)
Border (regular/irregular)	75 (n = 87)	66 (n = 72)	73 (n = 90)	69 (n = 69)
Morphology (homogeneous/heterogeneous)	82 (n = 87)	64 (n = 72)	73 (n = 98)	74 (n = 61)
Thickness + border + morphology	97 (n = 65)	65 (n = 46)	80 (n = 79)	94 (n = 32)

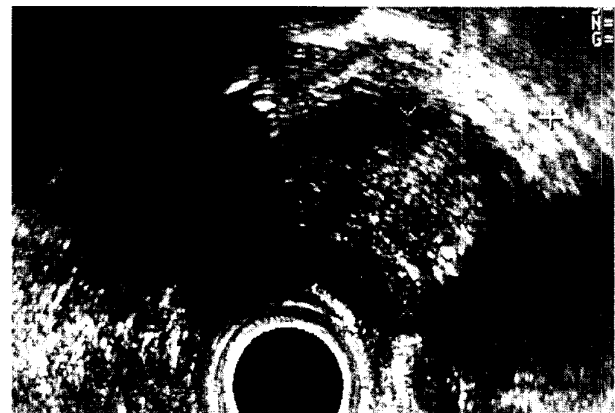


Figure 3 Sonographic view of an endometrial carcinoma with infiltration into the outer half of the myometrium. Histology: adenosquamous endometrial carcinoma with infiltration into the vicinity of the serous membrane

Table 5 Diagnostic accuracy of endometrial thickness (double layer) in patients with postmenopausal bleeding: a review of the literature

Authors	Year of publication	Number of patients	Endometrial thickness (mm)	Sensitivity (%)	Specificity (%)	Positive predictive value (%)	Negative predictive value (%)
Osmer et al. ⁴	1990	103	8	80	97	98	67
Granberg et al. ⁵	1991	205	5	100	96	87	—
Varnier et al. ⁶	1991	80	4	97	100	100	90
Auslender et al. ⁷	1993	129	3	100	92	93	100
Karlsson et al. ⁸	1993	105	5	97	81	72	98
Cacciatore et al. ⁹	1994	45	5	96	46	65	91
Chan et al. ¹⁰	1994	67	4	100	84	93	100
Zannoni et al. ¹¹	1994	761	4	63	67	69	60

with heterogeneous endometrial morphology as well as with an irregular endometrial border. Our results show that, compared to endometrial thickness, endometrial morphology and border characteristics alone do not enhance the diagnostic reliability of transvaginal sonography in diagnosing endometrial disease.

In contrast, using an endometrial thickness of ≤ 5 mm, homogeneous endometrial morphology and a regular endometrial border as diagnostic criteria, 94% of patients were found with benign histology and in only 6% was the histological finding suspicious, although no carcinomas were detected. The combined use of endometrial thickness at a cut-off level of 5 mm, endometrial morphology and endometrial border resulted in a sensitivity of 97%, specificity of 65%, positive predictive value of 80% and negative predictive value of 94%. Comparable results could not be obtained using either the endometrial thickness or the other two sonomorphological parameters alone (Table 4).

The results obtained in a study performed by Weigel and colleagues²¹ demonstrate the importance of the combined use of endometrial thickness and other sonomorphological parameters in improving the diagnostic accuracy of transvaginal sonography. The parameters used in this study included the homogeneity and echogenicity of the endometrial image as well as the presence of a central echo. An assessment of the endometrial border was not performed by these authors, although our results have shown that this parameter can play a role in the diagnosis of endometrial pathology. In our study, a sonographically detected regular endometrial border was associated with the histologically determined absence of carcinoma in 94% of cases and with the initiation of myometrial infiltration in only 6% of patients. These findings are supported by results obtained by Seelbach-Göbel and co-workers²², who also observed an increase in diagnostic accuracy when the endometrial border was used as an additional diagnostic parameter.

The use of morphological diagnostic parameters undoubtedly represents a qualitative assessment which is associated with the problem of reproducibility and investigator experience. However, the measurement of endometrial thickness with values in the millimeter range and the therapeutic consequences as a result of this measurement also depend upon the experience of the investigator^{23,24}. In the present study, the ultrasound scans were performed by three sonographers with several years of experience in the use of the technique. Each measurement of endometrial thickness was repeated three times; the inter- and intraobserver variability was below 5%.

Bourne and co-workers^{25,26} performed two studies to determine whether the use of color Doppler improved the reliability of transvaginal sonography and observed differences in uterine artery blood flow between patients with and patients without endometrial pathology. In a review article of 1995²⁷, the same author reached the conclusion that, on the basis of available data, color Doppler does not provide a demonstrable benefit for the detection of endometrial disease, although it may be useful in the assessment of myometrial invasion and tumor vascularity.

Transvaginal sonography will certainly not replace the histological examination. However, our results have demonstrated transvaginal sonography to be a valuable tool in reaching a decision as to further invasive investigations and therapy. The combined assessment of endometrial thickness, endometrial morphology and endometrial border improves the diagnostic accuracy of transvaginal sonography in patients with postmenopausal bleeding. Particularly in high-risk patients with a markedly increased anesthetic risk, transvaginal sonography is able to provide information as to whether surgical intervention is essential, or whether continued sonographic observation is sufficient. Furthermore, transvaginal sonography is a cost-efficient method for use in hospitals as well as for routine examinations in outpatient centers.

REFERENCES

- Disain PJ, Creasman WT. *Gynecologic Oncology*, 3rd edn. St Louis: CV Mosby, 1989: 161-97
- Daniel AG, Peters WA. Accuracy of office and operating room curettage in the grading of endometrial carcinoma. *Obstet Gynecol*, 1988;71:612-14
- Fleischer AC, Kalemieris GC, Machin JE, Eatmann SS, James AE Jr. Sonographic depiction of normal and abnormal endometrium with histopathologic correlation. *J Ultrasound Med* 1986;5:445-52
- Osmer R, Volksen M, Schauer A. Vaginosonography for early detection of endometrial carcinoma? *Lancet* 1990;335: 1569-71
- Granberg S, Wikland M, Karlsson B, Vorström A, Friberg G. Endometrial thickness as measured by endovaginal ultrasonography for identifying endometrial abnormality. *Am J Obstet Gynecol* 1991;164:47-52
- Varner RE, Sparks JM, Cameron CD, Roberts LL, Song SJ. Transvaginal sonography of the endometrium in postmenopausal women. *Obstet Gynecol* 1991;78:195-9
- Auslender R, Bornstein J, Dirnfeld M, Kogan O, Atad J, Abramovici H. Vaginal ultrasound in patients with postmenopausal bleeding. *Ultrasound Obstet Gynecol* 1993;3: 426-8
- Karlsson BS, Granberg S, Wikland M, Ryd W, Norström A. Endovaginal scanning of the endometrium compared to cytology and histology in women with postmenopausal bleeding. *Gynecol Oncol* 1993;50:173-8
- Cacciatore B, Tamsay T, Lehtovirta P, Ylöstalo P. Transvaginal sonography and hysteroscopy in postmenopausal bleeding. *Acta Obstet Gynecol Scand* 1994;73:413-16
- Chan FY, Chan MT, Pun TC, Lam C, Ngum HYS, Leong L, Wong RLC. Limitations of transvaginal sonography and colour Doppler imaging in the differentiation of endometrial carcinoma from benign lesion. *J Ultrasound Med* 1994;13: 623-8
- Zannoni E, Balestri M, Ferrazi F. L'ecografia transvaginale nella valutazione dell'endometrio in pazienti con perdite ematiche atipiche in postmenopausa. In D'Addario V, Cagnazzo G, eds. *ECO '94*. Bari: CIC Edizioni Internazionali, 1994;27-30
- Grimes D. Dilatation and curettage: a reappraisal. *Am J Obstet Gynecol* 1982;142:1-6
- Stovall T, Solomon S, Ling F. Endometrial sampling prior to hysterectomy. *Obstet Gynecol* 1980;73:405-9
- Stock R, Kanbaur A. Prehysterectomy curettage. *Obstet Gynecol* 1974;45:537-41
- Goldstein SR, Nachrigall M, Snyder RD, Nachrigall L. Endometrial assessment by vaginal ultrasonography before

- endometrial sampling in patients with postmenopausal bleeding. *Am J Obstet Gynecol* 1990;163:119–23
16. Karlsson B, Granberg S, Wikland M, Ylöstalo P, Torvid K, Marsal K, Valentin L. Transvaginal ultrasonography of the endometrium in women with postmenopausal bleeding – a Nordic trial. *Am J Obstet Gynecol* 1995;172:1488–94
 17. Merz E, Macchiella D, Mitze M. Die Vaginosonographie als nichtinvasives Hilfsmittel bei der Abklärung von Blutungen in der Postmenopause. *Ultraschall Klin Praxis* 1990;5:1–7
 18. Nasri MN, Coast GJ. Correlation of ultrasound findings and endometrial histopathology in postmenopausal women. *Br J Obstet Gynaecol* 1989;96:1333–8
 19. Weber G, Merz E, Bahlmann F, Mitze M, Weikel W, Knapstein PG. Assessment of myometrial infiltration and preoperative staging by transvaginal ultrasound in patients with endometrial carcinoma. *Ultrasound Obstet Gynecol* 1995;6:362–7
 20. Merz E, Miric-Tesanic D, Bahlmann F, Weber G, Wellek S. Sonographic size of uterus and ovaries in pre- and postmenopausal women. *Ultrasound Obstet Gynecol* 1996;7:38–42
 21. Weigel M, Friese K, Strittmatter H-J, Melchert F. Measuring the thickness – is that all we have to do for sonographic assessment of endometrium in postmenopausal women? *Ultrasound Obstet Gynecol* 1995;6:97–102
 22. Seelbach-Göbel B, Rempen A, Kirsten Y. Transvaginaler Ultraschall am Endometrium in der Postmenopause. *Geburtshilfe Frauenheilkd* 1995;55:59–64
 23. Duda VF, Juhnke J, Kaewel K, Rode G. Inter- und Intra-observergenauigkeit der vaginosonographischen Endometriumbewertung. *Ultraschall Klin Praxis* 1992;7:104–6
 24. Karlsson B, Granberg S, Ridell B, Wikland M. Endometrial thickness as measured by transvaginal sonography: inter-observer variation. *Ultrasound Obstet Gynecol* 1994;4:320–5
 25. Bourne TH, Campbell S, Whitehead MJ, Royston P, Steer C, Collins WP. Detection of endometrial cancer in postmenopausal women by transvaginal ultrasonography and colour flow imaging. *Br Med J* 1990;301:367–70
 26. Bourne TH, Campbell S, Steer CV, Royston P, Whitehead MJ, Collins WP. Detection of endometrial cancer by transvaginal ultrasonography with colour flow imaging and blood flow analysis: a preliminary report. *Gynecol Oncol* 1991;40:253–9
 27. Bourne TH. Evaluating the endometrium of postmenopausal women with transvaginal ultrasonography. *Ultrasound Obstet Gynecol* 1995;6:75–80