

2011 Terminology of the Vulva of the International Federation for Cervical Pathology and Colposcopy

Jacob Bornstein, MD, MPA,¹ Mario Sideri, MD,² Silvio Tatti, MD,³ Patrick Walker, MD,⁴ Walter Prendiville, MD,⁵ and Hope K. Haefner, MD,⁶
For the Nomenclature Committee of the International Federation
for Cervical Pathology and Colposcopy

¹Department of Obstetrics & Gynecology, Western Galilee Hospital, and Bar-Ilan University Galilee Faculty of Medicine, Nahariya, Israel; ²Preventive Gynecology Unit, Gynecology Division, European Institute of Oncology, Milan, Italy; ³University of Buenos Aires, Buenos Aires, Argentina; ⁴Department of Gynaecology, Royal Free Hospital, London, UK; ⁵The Beacon Hospital, Sandyford, Dublin, Ireland; and ⁶Department of Obstetrics and Gynecology, L4000 Women's Hospital, The University of Michigan Hospitals, Ann Arbor, MI

■ Abstract

Objective. This study aimed to present the clinical and colposcopic terminology of the vulva (including the anus) of the International Federation of Cervical Pathology and Colposcopy.

Materials and Methods. The terminology has been developed by the International Federation of Cervical Pathology and Colposcopy Nomenclature Committee during 2009–2011.

Results. The terminology is part of a comprehensive terminology of the lower genital tract, allowing for standardization of nomenclature by colposcopists, clinicians, and researchers taking care of women with lesions in these areas. The terminology includes basic definitions and normal findings that are important for the clinician

lacking experience with management of vulvar disease. This terminology introduces definitions for abnormal findings recently accepted by the International Society for the Study of Vulvovaginal Disease and includes patterns to identify malignancy.

Conclusions. The terminology differs from past terminologies in that it includes colposcopic patterns and anal colposcopy. Nevertheless, the role of the colposcope in the management of vulvar disease is limited. ■

Key Words: vulva, colposcopy, anus, ISSVD, IFCPC

For many clinicians, the diagnosis of vulvar diseases presents an enigma. One of the reasons is that, for many years, there was no classification of these diseases that has been completely agreed on by the various clinical specialists (gynecologists, dermatologists, proctologists, and gastroenterologists) dealing with vulvar, including anal, diseases [1]. In addition, physical therapists, psychologists and sex therapists also provide care to patients affected by diseases of these areas. Pathologists used nomenclature for these diseases, which differed from the clinicians' terminology. The founding of interdisciplinary societies, such as the International Society for the Study of Vulvovaginal Disease (ISSVD),

Reprint requests to: Jacob Bornstein, MD, MPA, Department of Obstetrics and Gynecology, Western Galilee Hospital, PO Box 21, Nahariya 22100, Israel. E-mail: mdjacob@gmail.com

Dr Walker was the president of International Federation of Cervical Pathology and Colposcopy, 2008–2011.

The 2009–2011 International Federation of Cervical Pathology and Colposcopy nomenclature committee: Jacob Bornstein, James Bentley, Peter Bösze, Frank Girardi, Hope Haefner, Michael Menton, Myriam Perrotta, Walter Prendiville, Peter Russell, Mario Sideri, Björn Strander, Silvio Tatti, Aureli Torne, and Patrick Walker.

© 2012, American Society for Colposcopy and Cervical Pathology
Journal of Lower Genital Tract Disease, Volume 16, Number 3, 2012, 00–00

helped to establish an ongoing dialog between representatives of the different disciplines in an attempt to arrive at an accepted nomenclature for diagnostic and therapeutic procedures [2, 3].

However, there are more players in the field. Many women affected by diseases of the vulva are referred for care to colposcopy clinics. Colposcopists take care of women with abnormal Pap smears. However, they are also experienced in treating human papillomavirus (HPV)-related diseases and intraepithelial neoplasia of the whole lower genital tract. They use the colposcope—a magnifying optical tool; they are capable of documenting the lesions and are experienced in administering treatment by carbon dioxide (CO₂) laser, diathermy, and cryotherapy, which are appropriate therapies for lower genital tract lesions. In addition, there has recently been an increase in the incidence of the diagnosis of anal intraepithelial neoplasia (AIN), a precursor of anal carcinoma [4]. The high-resolution anoscopy examination, used to detect intraepithelial and invasive anal neoplasia, is basically colposcopy of the anus, and the treatment of this precancerous anal condition also involves use of the CO₂ laser, cryotherapy, and other destructive modalities found in colposcopy clinics.

Nevertheless, although colposcopists use the terminology of the International Federation for Cervical Pathology and Colposcopy (IFCPC) to report the cervical findings, there was no IFCPC terminology for vulvar patterns (including the anal region) recognized during the clinical or the colposcopic examination [5]. Clinicians who tried to use the terminology for vulvar disease of the ISSVD, the guardian organization of vulvar diseases, found that it did not include pattern recognition terminology but was rather a classification according to disease pathophysiology [2, 3]. Hence, the reporting of vulvar findings has been inconsistent.

Therefore, the IFCPC nomenclature committee, which was established at the 2008 IFCPC world congress in Auckland, New Zealand, took on itself the task of creating a comprehensive, “total” lower genital tract colposcopic terminology, not only of cervical and vaginal colposcopy findings [6] but also of the vulvar, perineal, perianal, and anal regions. For that purpose, a subcommittee to establish the terminology of vulvar conditions was set up, headed by Dr Jacob Bornstein, MD, MPA, which included doctors Mario Sideri, MD, and Hope Haefner, MD. The IFCPC current and presidents-elect—Drs Patrick Walker, Silvio Tatti, and Walter Prendiville—also participated in the deliberations. The discussions were

carried out through a dedicated Web site, by e-mail, and at meetings. The vulvar (including the anal) clinical and colposcopic terminology was accepted by the general assembly of the IFCPC at the 2011 World congress in Rio de Janeiro, Brazil, and was finalized in March 2012. The aim of the IFCPC was to create the terminology that would take into account the new ISSVD vulvar terminology, as well as add terminologies specific to other regions and be compatible with colposcopy. Therefore, only after the new ISSVD terminology was ready [7] did the IFCPC vulvar nomenclature subcommittee complete its deliberations.

As the representative body of the national societies of colposcopy and cervical pathology, the IFCPC recommends that the 2011 vulvar (including the anus) terminology be implemented without delay for diagnosis, treatment, and research purposes.

THE STRUCTURE OF THE VULVAR TERMINOLOGY

The vulvar terminology table includes several sections (Table 1).

The first part is the section on **basic definitions**. It describes the various structures of the vulva and anus and their composition—skin or mucosa. Although some conditions affect both skin and mucosa, many diseases are unique to the skin alone or to the mucosa alone. We further divided the skin into “hairy” (e.g., labia majora) and “nonhairy” (e.g., clitoris), as hairy skin harbors skin appendages, which may be involved in a variety of diseases, affecting their treatment, such as vulvar intraepithelial neoplasia (VIN). This should affect the consideration for excision of VIN in hair-bearing areas versus CO₂ laser vaporization in non-hair-bearing areas, for example.

The **normal findings** section includes micropapillomatosis, sebaceous glands (Fordyce spots), and vestibular redness. As stated earlier, the rationale is to educate the clinicians that these are normal findings. Vestibular redness alone is not a sign of dermatitis or inflammation.

The remainder of the terminology table is composed of pattern recognition nomenclature that can be arrived at with or without a colposcope or a magnifying lens. Once the pattern has been recognized, further evaluation and differential diagnosis may be carried out.

The **abnormal findings** of the vulvar terminology include various variables that characterize each lesion by its size, location, type, color, and secondary morphology, if present. Because these terms are novel to colposcopists, Tables 2 and 3 detail their definitions.

Table 1. The 2011 IFCPC Clinical/Colposcopic Terminology of the Vulva (Including the Anus)

Section	Pattern			
Basic definitions	<p>Various structures: Urethra, Skene duct openings, clitoris, prepuce, frenulum, pubis, labia majora, labia minora, interlabial sulci, vestibule, vestibular duct openings, Bartholin duct openings, hymen, fourchette, perineum, anus, anal squamocolumnar junction (dentate line)</p> <p>Composition: Squamous epithelium: hairy/nonhairy, mucosa</p>			
Normal findings	Micropapillomatosis, sebaceous glands (Fordyce spots), vestibular redness			
Abnormal findings	<p>General principles: size in centimeters, location</p> <table border="0"> <tr> <td style="vertical-align: top;"> <p>Lesion type:</p> <ul style="list-style-type: none"> • Macule • Patch • Papule • Plaque • Nodule • Cyst • Vesicle • Bulla • Pustule </td> <td style="vertical-align: top; padding-left: 20px;"> <p>Lesion color:</p> <ul style="list-style-type: none"> • Skin-colored • Red • White • Dark </td> <td style="vertical-align: top; padding-left: 20px;"> <p>Secondary morphology:</p> <ul style="list-style-type: none"> • Eczema • Lichenification • Excoriation • Purpura • Scarring • Ulcer • Erosion • Fissure • Wart </td> </tr> </table>	<p>Lesion type:</p> <ul style="list-style-type: none"> • Macule • Patch • Papule • Plaque • Nodule • Cyst • Vesicle • Bulla • Pustule 	<p>Lesion color:</p> <ul style="list-style-type: none"> • Skin-colored • Red • White • Dark 	<p>Secondary morphology:</p> <ul style="list-style-type: none"> • Eczema • Lichenification • Excoriation • Purpura • Scarring • Ulcer • Erosion • Fissure • Wart
<p>Lesion type:</p> <ul style="list-style-type: none"> • Macule • Patch • Papule • Plaque • Nodule • Cyst • Vesicle • Bulla • Pustule 	<p>Lesion color:</p> <ul style="list-style-type: none"> • Skin-colored • Red • White • Dark 	<p>Secondary morphology:</p> <ul style="list-style-type: none"> • Eczema • Lichenification • Excoriation • Purpura • Scarring • Ulcer • Erosion • Fissure • Wart 		
Miscellaneous findings	<ul style="list-style-type: none"> • Trauma • Malformation 			
Suspicion of malignancy	Gross neoplasm, ulceration, necrosis, bleeding, exophytic lesion, hyperkeratosis With or without white, gray, red, or brown discoloration			
Abnormal colposcopic/other magnification findings ^a	Acetowhite epithelium, punctation, atypical vessels, surface irregularities Abnormal anal squamocolumnar junction (note location about the dentate line)			

^aSee explanatory text.

The **miscellaneous findings** may describe various traumatic insults to the vulva such as hematoma, and the **“suspicion of malignancy”** contains patterns that should be biopsy examined so as to rule in or rule out vulvar cancer.

The last section of the terminology describes the **abnormal colposcopic/other magnification findings** and contains the colposcopic recognition of intraepithelial neoplasia of the vulva, perineum, perianal, and anal areas.

Colposcopy of the vulva after the application of acetic acid is discouraged as a routine examination; it can be useful where genital condylomata acuminata, intraepithelial neoplasia, or early invasive cancer is suspected by inspection with the naked eye or with magnification, in both the vulvar and the anal areas. Colposcopic ex-

amination after the application of acetic acid (“vulvoscopy,” “anoscopy”) helps to delineate the lesion and choose the biopsy site. However, it should be underlined that the finding of acetowhitening alone is not specific on the vulva.

DISCUSSION

The decision of the IFCPC nomenclature committee to publish a terminology for the vulva (including the anus) for colposcopists was debated by colposcopists and vulvar experts during the 3-year period of the activity of the Nomenclature Committee for several reasons: colposcopists traditionally examine the cervix with a colposcope after staining it with 3% to 5%

Table 2. Definitions of Primary Lesion Types⁷

Term	Definition
Macule	Small (<1.5 cm) area of color change; no elevation and no substance on palpation
Patch	Large (>1.5 cm) area of color change; no elevation and no substance on palpation
Papule	Small (<1.5 cm) elevated and palpable lesion
Plaque	Large (>1.5 cm) elevated, palpable, and flat-topped lesion
Nodule	A large papule (>1.5 cm); often hemispherical or poorly margined; may be located on the surface, within, or below the skin; nodules may be cystic or solid
Vesicle	Small (<0.5 cm) fluid-filled blister; the fluid is clear (blister: a compartmentalized, fluid-filled elevation of the skin or mucosa)
Bulla	A large (>0.5 cm) fluid-filled blister; the fluid is clear
Pustule	Pus-filled blister; the fluid is white or yellow

Table 3. Definitions of Secondary Morphology Presentation

Term	Definition
Eczema	A group of inflammatory diseases that are clinically characterized by the presence of itchy, poorly marginated red plaques with minor evidence of microvesiculation and/or, more frequently, subsequent surface disruption
Lichenification	Thickening of the tissue and increased prominence of skin markings. Scale may or may not be detectable in vulvar lichenification. Lichenification may be bright-red, dusky-red, white, or skin colored in appearance
Excoriation	Surface disruption (notably excoriations) occurring as a result of the "itch-scratch cycle"
Erosion	A shallow defect in the skin surface; absence of some, or all, of the epidermis down to the basement membrane; the dermis is intact
Fissure	A thin, linear erosion of the skin surface
Ulcer	Deeper defect; absence of the epidermis and some, or all, of the dermis

acetic acid to detect intraepithelial neoplasia. On the cervix, colposcopy evaluates a small area, the transformation zone, under different circumstances. However, the vulva has an anatomic structure different from the cervix because it is composed of skin and mucosa [8]. The colposcope itself is not a necessary instrument for dealing with vulvar diseases because many experts who examine and treat vulvar disease are providers, of whom many do not use colposcopes and do not apply acetic acid to stain the vulvar tissue. Some of these providers were concerned that introducing a colposcopic terminology of vulvar disease might erroneously imply that vulvar disease should be taken care of only by colposcopists. To address this concern, the current terminology has been entitled, "2011 IFCPC clinical/colposcopic terminology," and it includes an explanation of the limited role of the colposcope in the diagnosis of vulvar disease.

On the other hand, many physicians who take care of the vulva are gynecologists and most of them are colposcopists, so gynecologists who usually deal with cervical precancer diagnosis and widely use the colposcope support the introduction of vulvar terminology into the IFCPC nomenclature. In a poll carried out in 2010 by the Spanish colposcopy society, chaired by Dr Aureli Torne, 70.8% of the 178 members who responded believed that the IFCPC colposcopy nomenclature should include a nomenclature of the vulva and vagina in addition to the cervix (A. Torne, 2009, personal communication). Indeed, terminology of the vagina has been added to the cervical terminology [6]. Moreover, many colposcopists, as part of evaluating patients with cervical intraepithelial lesions, look for VIN, perianal intraepithelial neoplasia (PAIN), or AIN [9–11]. The term *vulvoscopy* is in widespread use and refers to an examination of the vulva by a colposcope [12]. Several texts and articles on the use of vulvoscopy to diagnose vulvar lesions have been published [13–16]. However, because

of the lack of dedicated terminology, the reporting of vulvar findings has been inconsistent. In addition, in locations where there is a paucity of vulvar experts, colposcopists are referred patients with various vulvar symptoms, such as pruritus or pain, where the cause is ultimately found to be a dermatological vulvar or perianal lesion.

The IFCPC board agreed to the nomenclature committee proposal to take on itself the task of preparing the vulvar terminology for clinicians and colposcopists. The reasons for preparing a separate IFCPC vulvar terminology rather than simply referring members to the new ISSVD terminology [7] were the following: the ISSVD includes members who are already expert in vulvar diseases and the ISSVD terminology is rather complex, requiring some in-depth knowledge in the field. For this reason, it does not contain a section on "basic definitions" and "normal findings." These may be redundant for expert vulvologists but essential for the novice clinician inexperienced in dealing with vulvar lesions. For example, micropapillomatosis (see Figure 1) or Fordyce spots, which are normal vulvar findings, are still mistakenly diagnosed by some as genital condylomata acuminata and treated by CO₂ laser vaporization. We felt that, in an IFCPC terminology, it should be clear that micropapillomatosis and Fordyce spots are normal findings. The terminology is supposed to be educational for those who are not familiar with the study of vulvar disease and assist in directing the diagnosis and treatment of vulvar diseases even for the non-expert vulvologist. Another reason for producing a separate IFCPC vulvar terminology was that the ISSVD terminology does not include a colposcopic terminology, nor does it have specific terminology for anal lesions, but covers only vulvar lesions.

As to the controversy of whether the colposcope and acetic acid application have a role in the diagnosis and treatment of vulvar disease, many members of the

Fig 1 4/C

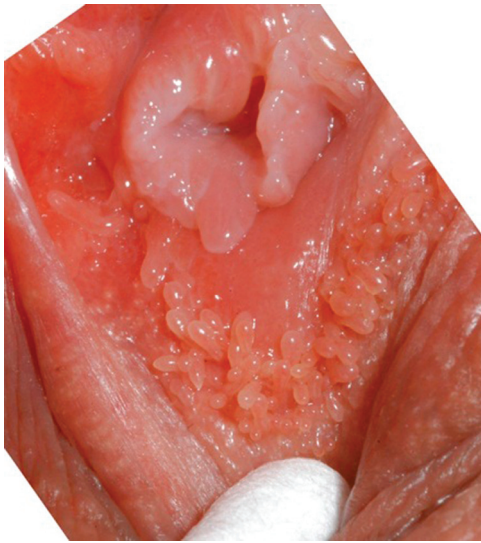


Figure 1. Labial micropapillomatosis, a normal finding.

IFCPC believe that there is a use for the colposcope in vulvar examination. For example, it can be used to clearly delineate cases suspected of VIN or early stromal invasion. A poll of several prominent experts of vulvar disease (R. Jones, MD, and A. Maclean, MD, 2009, personal correspondence of ISSVD past presidents) clearly supports the use of the colposcope for vulvar examination, mainly for VIN and early vulvar cancer. However, although for the cervix, the use of acetic acid is mandatory for any single examination, and without acetic acid most of the information coming from the examination is lost; on the vulva, acetic acid application is very limited to the rare cases where VIN or early stromal invasion is suspected. On the other hand, health care providers who object to the use of colposcopy for the vulva, do use a magnifying glass, and some have developed “dermoscopy,” which is an optical magnifying tool to better diagnose skin lesions [17]. So although colposcopy of the vulva is very different from colposcopy of the cervix, magnification is very helpful for many lesions, whereas the use of acetic acid is often inconvenient and only useful in selected instances.

As a result of this discussion, it became apparent that, because many providers do not use the colposcope, it is the task of colposcopists to prepare a terminology of colposcopic findings. To reach a consensus with the ISSVD, we introduced the terms of vulvar pattern recognition from the new ISSVD terminology into the “abnormal findings” section of the IFCPC nomenclature, with the consent of the terminology committee chairman. In addition, as stated earlier, only the last sec-

tion of the IFCPC terminology describes colposcopy of the vulva and anus.

We hope that this new terminology of the vulva will help familiarize health care providers who have not been taking care of women with vulvar disease so far, with the approach to vulvar disease and improve the quality of care for patients with vulvar conditions.

REFERENCES

1. Micheletti L, Preti M, Bogliatto F, Lynch PJ. Vulvology: A proposal for a multidisciplinary subspecialty. *J Reprod Med* 2002;47:715–7.
2. Lynch PJ, Moyal-Barracco M, Bogliatto F, Micheletti L, Scurry J. 2006 ISSVD classification of vulvar dermatoses: pathologic subsets and their clinical correlates. *J Reprod Med* 2007;52:3–9.
3. Moyal-Barracco M, Lynch PJ. 2003 ISSVD terminology and classification of vulvodynia: a historical perspective. *J Reprod Med* 2004;49:772–7.
4. Swedish KA, Lee EQ, Goldstone SE. The changing picture of high-grade anal intraepithelial neoplasia in men who have sex with men: the effects of 10 years of experience performing high-resolution anoscopy. *Dis Colon Rectum* 2011; 54:1003–7.
5. Walker PG, Dexeus S, De Palo G, Barrasso R, Campion M, Girardi F, et al. International terminology of colposcopy: an updated report from the International Federation for Cervical Pathology and Colposcopy. *Obstet Gynecol* 2003;101:175–7.
6. Bornstein J, Bentley J, Bösze P, Girardi F, Haefner H, Menton M, et al. 2011 Colposcopic Terminology of the International Federation for Cervical Pathology and Colposcopy. *Obstet Gynecol* 2012 (in press).
7. Lynch PJ, Moyal-Barracco M, Scurry J, Stockdale C. 2011 ISSVD Terminology and Classification of Vulvar Dermatological Disorders: an approach to clinical diagnosis. *J Lower Gen Tract Dis* 2012 (in press).
8. Micheletti L, Bogliatto F, Lynch PJ. Vulvoscopy: review of a diagnostic approach requiring clarification. *J Reprod Med* 2008;53:179–82.
9. Wright VC, Chapman WB. Colposcopy of intraepithelial neoplasia of the vulva and adjacent sites. *Obstet Gynecol North Am* 1993;20:231–55.
10. Skyes P, Smith N, McCormick P, Frizelle FA. High grade vulvar intraepithelial neoplasia (VIN3): a retrospective analysis of patient characteristics, management, outcome and relationship to squamous cell carcinoma of the vulva 1989–1999. *Aust NZ J Obstet Gynecol* 2002;42:69–74.
11. Rodolakis A, Diakomanolis E, Vlachos G, Iconomou T, Protopappas A, Stefanidou C, et al. Vulvar intraepithelial neoplasia (VIN)—diagnostic and therapeutic challenges. *Eur J Gynecol Oncol* 2003;24:317–22.

12. Van Beurden M, van de Vange N, de Craen AJ, Tjong-A-Hung SP, ten Kate FJ, ter Schegget J, et al. Normal findings in vulvar examination and vulvoscopy. *Br J Obstet Gynaecol* 1997;104:320–4.
13. Hatch K. Colposcopy of vaginal and vulvar human papillomavirus and adjacent sites. *Obstet Gynecol Clin North Am* 1993;20:203–15.
14. Ritter J, Baladuf JJ, Philippe E, Dreyfus M, Dillmann JC. Colposcopy of the vulva. *J Gynecol Obstet Biol Reprod (Paris)* 1991;20:511–8.
15. Sener AB, Kuscu E, Seekin NC, Gokmen O, Taner D, Cobanoglu O, et al. Postmenopausal vulvar pruritus—colposcopic diagnosis and treatment. *J Pak Med Assoc* 1995;45:315–7.
16. Gagné HM. Colposcopy of the vagina and vulva. *Obstet Gynecol Clin North Am* 2008;35:659–69.
17. Lallas A, Kyrgidis A, Tzello TG, Apalla Z, Karakyriou E, Karatolias A, et al. Accuracy of dermoscopic criteria for the diagnosis of psoriasis, dermatitis, lichen planus and pityriasis rosea. *Br J Dermatol* 2012 (in press).